

THREE-DIMENSIONAL RECONSTRUCTION OF A COMPLEX IATROGENIC DEFECT THROUGH A COMBINATION OF ORTHODONTIC AND AUGMENTATION APPROACHES

Chakkanov Fakhritdin Khusanovich

Assistant Department of Orthopedic Dentistry

Samarkand State Medical University Samarkand, Uzbekistan

Abstract

Despite the huge popularity of using dental implants in the practice of a dentist, the number of complications and risks associated with their use still remains at a fairly high level. In some cases, the causes of the formation of gingival-alveolar defects, especially in the aesthetic field, are precisely iatrogenic errors by doctors who do not ensure the proper quality of implantation and augmentation procedures.

Introduction

With a high level of smile, the treatment of such complications is quite risky, given the medical and legal consequences of such types of interventions. The most difficult task is precisely to restore the ideal gingival architecture with parallel use for the rehabilitation of dental implant structures. The treatment of alveolar ridge defects often takes place through surgical interventions with separation of the mucous-gingival flap. Taking into account the volume of necessary bone reconstruction, the area of the formed flap of soft tissues can increase accordingly. At the same time, however, the risk of potential complications increases, which include incomplete wound closure, the formation of digressions, which provoke exposure of the membrane or graft area, infection and unpredictable changes in the surgical sites.

Evaluation of the predictability of bone augmentation procedures in the aesthetic area should take into account the features of the final architecture of soft tissues in the periimplant area. With this approach, it is possible to determine the feasibility of implementing a minimally invasive approach or a combination of different treatment methods such as orthodontic tooth extrusion, distractive osteogenesis.

The purpose of this article is to demonstrate a clinical case using an interdisciplinary approach, including targeted tooth extrusion using the minimally invasive subperiosteal aesthetic ridge-augmentation technique (SMART) for the comprehensive treatment of iatrogenic gingival-alveolar defect.

A Clinical Case

A somatically healthy 20-year-old woman sought dental help due to the need to treat a defect in the area of missing tooth 7. The patient had a pronounced high smile line, in which the dental defect was clearly visualized, in addition, she had pain and sensitivity of teeth 6 and 8 (photo 1). Although the patient used the Essix retainer, a significant amount of deformation of the dentition and loss of surrounding tissues limited the effectiveness of this approach to restoring her smile. Previously, she underwent comprehensive orthodontic treatment, part of which involved the formation of an adequate amount of space to restore the innately missing right lateral incisor. At the end of the orthodontic phase of rehabilitation, bone augmentation and implantation were performed in this area. Due to the failure of both procedures, an even greater dental defect has formed, which violates the parameters of not only hard but also soft tissues. Repeated intervention on bone tissues led to the formation of an even greater deficiency and increased recessions in the area of 6 and 8 teeth. After these results, the patient decided to abandon bone reconstruction as a treatment option and began to look for alternative ways to complete rehabilitation.

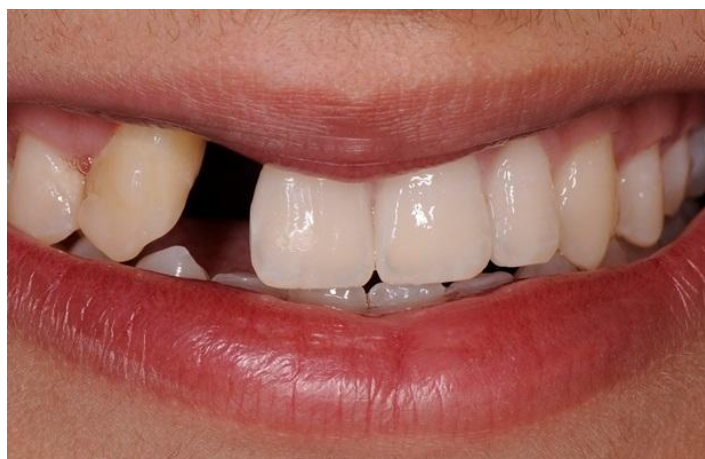
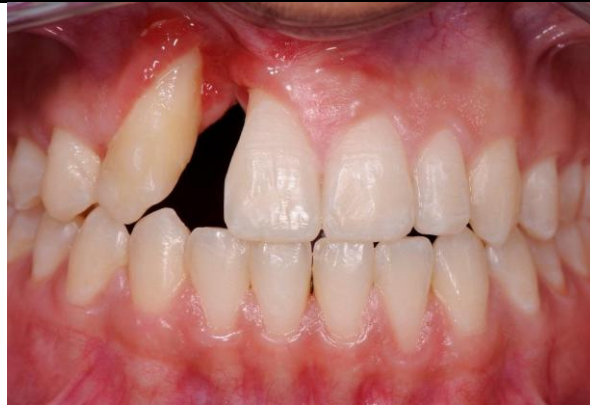
Photo 1. Type of deformity due to the congenital absence of the right lateral incisor.

Clinical examination

During the clinical examination, it was possible to establish a deficiency of tissues of the alveolar bone and surrounding gums in the area of the upper right lateral incisor. The defect of the bone crest spread both vertically and horizontally, which was associated with the loss of periodontal attachment in the area of adjacent 6 and 8 teeth. Although the depth of probing was within the normal range, there were signs of inflammation in the gum area. Plaque removal was difficult due to soft tissue defects, the location of the marginal gum, and irregularities in the gingival profile architecture. The presence of bone sequestration could also be observed through the mucous membrane from the buccal side of the crest (Photo 2).



The results of the tomographic examination made it possible to visualize a large three-dimensional defect in which the vertical component extended almost to the apical third of teeth 6 and 8. In addition, in the area of tooth 5, a digiscence of the buccal plate was detected, as well as a thinning of the vestibular cortical component, which was caused by orthodontic treatment (photos 3 and 4).

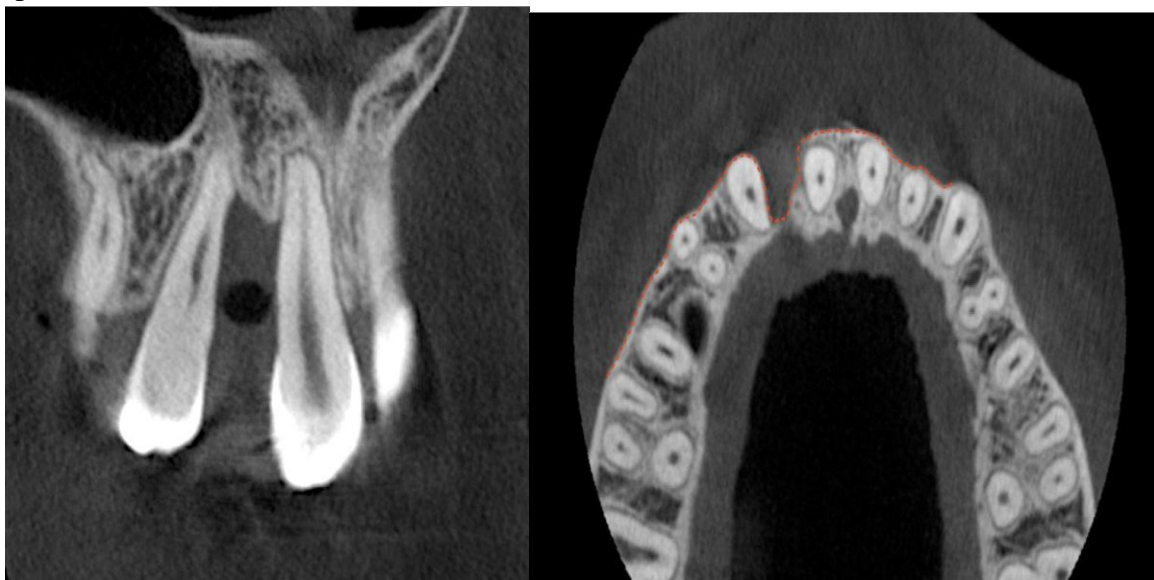


Photo 3-4. The CT scan showed an expansion of the defect to the apical thirds of the 6th and 8th teeth, and the presence of bone degeneration in the area of the 5th tooth.

Justification of implantological treatment in the aesthetic area

Determining the aesthetic and restorative goals of treatment is a primary planning task. In this case, teeth 6 and 8 had to be removed and replaced with the formed area of the adentia by means of implants. Given the high line of the smile and the volume of the formed defect, it was predicted that the additional use of restoration materials that mimic the color of the gums simply cannot be dispensed with. The aesthetic results of the implantation procedure largely depend on the architecture of the soft tissues in the periimplant area. Preliminary publications have already reported on the sufficient predictive nature of rehabilitation results when using the protocol of immediate implantation into postextraction wells. After such treatment, Lee and colleagues reported minimal changes in the thickness of the buccal cortical plate after 6 months,

while Chu confirmed only a slight remodeling of the labial gum profile during the implementation of a similar approach. Despite a significant number of publications describing various techniques of implantation in the aesthetic field, there is still a consensus decision that the primary factors determining success are precisely the doctor's experience and the choice of an adequate site of intervention in the context of the implementation of flap-free surgical access and the principles of using dispensary structures. Thus, in order to carry out a certain implantation intervention, it may first be necessary to prepare the jaw area through augmentation procedures in order to minimize possible potential risks. Although the areas of 6 and 8 teeth were quite compromised, immediate implantation and the use of dental crowns in these areas will help to maximize the volume of soft and hard tissues, which means that such treatment in itself can be described as the most predictable.

Aesthetic predictability of bone augmentation procedures

It has been proven that bone augmentation procedures are effective in forming adequate volumes of surrounding support for the area in which the implant placement procedure will be performed in the future. However, it must not be forgotten that these procedures also significantly affect changes in the profile of soft tissues in the aesthetic area. Several authors have reported that bone augmentation, targeted bone regeneration (BCR), and flap separation techniques provoke an increased risk of complications potentially compromising aesthetics in the peri-implant site. These include the formation of scars, gingival defects, recessions, reduction of the interdental papilla, especially with a thin biotype of soft tissues. In addition, this patient had a large iatrogenic defect with a significant vertical component, so it was necessary to ensure maximum predictability of the augmentation procedure. As a result of Merli studies, it was found that the level of total complications during vertical augmentation was 54% when compared with the results of reconstruction using autogenic bone grafts with resorbable membranes and membranes reinforced with titanium plates. In subsequent studies using resorbable and non-resorbable barriers, Merli reported a slightly lower degree of complications in 41%. Complications included membrane exposure, wound infection, and graft loss. In both studies, the analysis was performed in the area of the distal jaw areas, and the procedures were performed only by highly qualified clinicians with more than 20 years of experience. Due to the existing high risk of complications in this case, based on the results of preliminary iatrogenic interventions, the complexity of the structure of the formed defect, the parameters of the aesthetic area and the criteria for the height of the smile, traditional approaches to augmentation were not acceptable enough. Consequently, the possibility of implementing other alternative treatment approaches was analyzed.

Orthodontic tooth extrusion

Bone remodeling associated with orthodontic displacement follows the basic principles described by Reitan. When the tooth moves in a certain direction, bone resorption occurs on the side of applying pressure to the periodontal ligament, while bone tissue apposition occurs on the opposite side. In 1973, Brown reported that orthodontic treatment may be associated with

the development of periodontal defects and changes in the initial parameters of soft and hard tissues. In an already classic article, Ingber described the use of orthodontic extrusion in order to restore formed bone defects. Pontoriero demonstrated that a similar approach can also be used to correct the level of bone tissue in the interproximal areas. Ingber subsequently reported on the advantages of soft tissue remodeling associated with orthodontic extrusion in restoring the necessary cosmetic profile of the gums. Salama and colleagues later described a case of orthodontic extrusion in the treatment of hopeless teeth: the implemented approach helped to achieve not only the necessary remodeling of soft and hard tissues, but also ensured the formation of sufficient conditions for the further installation of a bone implant. Given the similar predictability of this method in order to restore the vertical components of the bone ridge, it was chosen as the main one during the comprehensive rehabilitation of the dental patient described above (Photo 5).

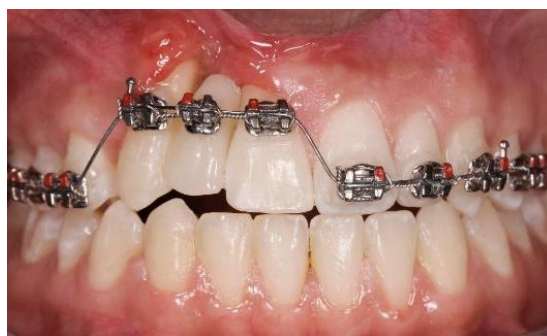

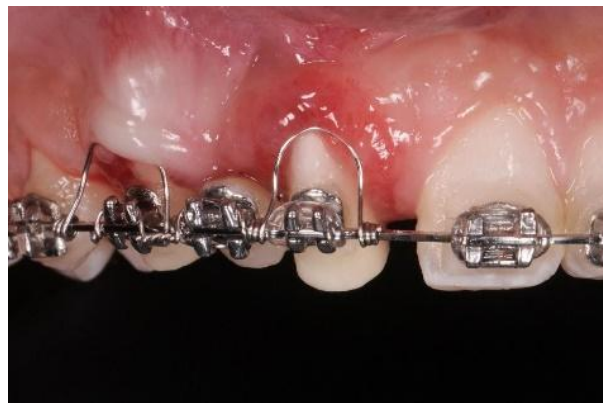Photo 5. The beginning of the orthodontic phase of treatment.

During orthodontic extrusion, only stretching forces act on the periodontal ligament, which allows bone tissue to be positioned in the area of the well walls. This procedure is monitored by ensuring complete root extrusion without compromising the integrity of the walls and bottom of the bone bed. With a sufficiently good periodontal status, coronal proliferation of the connective dental apparatus also occurs in conditions of bone apposition. During such a procedure, it is also important to ensure the control of occlusal ratios, since the formation of premature contacts can provoke labial migration of the tooth, and hence resorption of the vestibular cortical plate. Therefore, the author recommends providing a 2.5 mm occlusal gap before starting the orthodontic extrusion procedure, and performing the necessary occlusal correction every week during monitoring. The dynamics of extrusion can vary from patient to patient, therefore, patients should fully understand the need for periodic monitoring to detect the first contact with the antagonist tooth.

In this clinical case, supracrestal fiber fibrotomy was performed from the mesial side of the 8th tooth and the distal side of the 6th tooth every two weeks. Sometimes successful results of applying the principles of orthodontic extrusion imply achieving a state of excessive compensation in relation to the physiological parameters of the geometry of hard and soft tissues. In this clinical case, the necessary architectonics of the gingival-alveolar complex of the well required extrusion of the 6th tooth to the level of the apical third of the 8th tooth. As

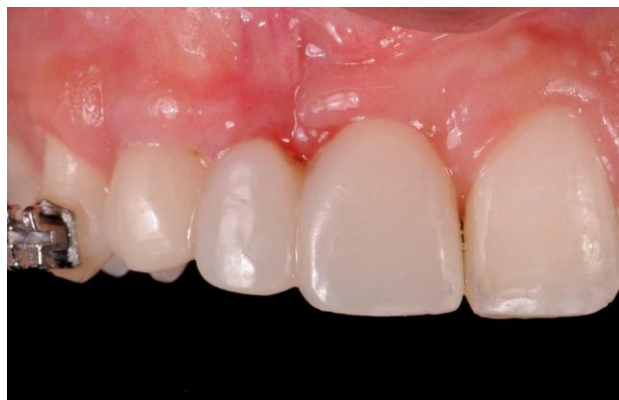the gingival sulcus moves and seems to turn out, it is possible to notice the appearance of red spots on the surface of the gum, which, in fact, are non-keratinized furrowed epithelium. Later, this tissue transforms into keratinized gum under the influence of the oral environment. Sometimes, during orthodontic extrusion, signs of linguistic displacement may develop, which must be immediately corrected by orthodontic factors of action (photos 6 and 7).

Photos 6-7. To achieve the necessary ridge parameters in the area of the defect, it was necessary to ensure the directional extension of 6 and 8 teeth. With such a volume of orthodontic eruption, lingual tooth displacement is observed, which must be corrected immediately. Inversion of the sulcate epithelium may occur.



After completion of this phase of treatment, the teeth should be splinted for a period of 3 months, which allows the surrounding osteoid tissue to undergo the necessary mineralization, as well as ensure proper gum remodeling. In this clinical case, the degree of orthodontic extrusion was so great that after such an operation, excessive tooth mobility was noted, which limited the possibility of immediate temporary restoration. Instead, a straight composite splint with metal reinforcement in the area of teeth 6-8 was formed (photos 8 and 9).

Photos 8-9. Achieving adequate ridge height and soft tissue profile parameters. After that, the composite tire is fixed for 3 months. Keratinization of the sulcate epithelium is also observed during this period.



Compared with the preoperative condition (Photo 2), photos 8 and 9 demonstrate the result of the orthodontic phase of rehabilitation. The restoration of adequate alveolar height was

achieved under conditions of improved soft tissue architecture, and the inverted sulcate epithelium in the area of tooth 8 was completely keratinized. However, the pre-existing defect still appeared as a residual gap. After 3 months of the stabilization period, a CT scan was performed to plan the further rehabilitation process. The fact of bone tissue growth in the vertical direction, including in the adentia area, was visualized on the slices (photos 10-12). The apex of the 8th tooth was extruded from the area of the well and was simply visualized in the surrounding soft tissues.

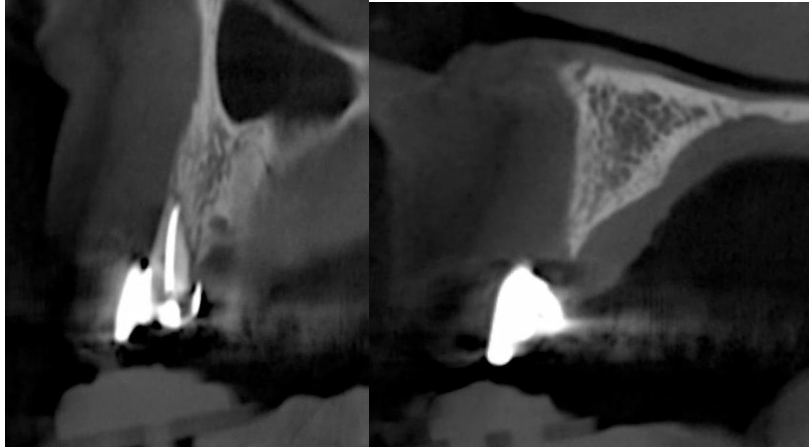


Photo 10. A tomographic section of the 6th tooth shows an increase in the vertical parameters of the bone ridge.

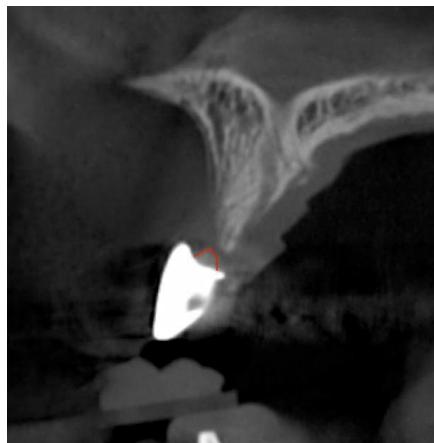


Photo 11. A tomographic section of the 7th tooth demonstrates an increase in the vertical parameters of the bone ridge.

Minimally invasive bone augmentation

The available data suggest that surgical augmentation techniques with flap separation can compromise aesthetic parameters in the periimplant area. A minimally invasive approach, on the contrary, helps to minimize the risk of such complications and the general postoperative discomfort of the patient. Despite the fact that augmentation methods with tunnel access formation and the use of a granular graft have been described in practice, they have not become widespread. Recent studies have focused more on soft tissue augmentation using tunnel access.

The author published a series of clinical cases in which he implemented the mini-invasive SMART technique, thanks to which he managed to achieve effective results in the field of 60 surgical sites, which were confirmed by both a 30-month follow-up period and data obtained during histological examinations. The average increase in the horizontal parameters of the ridge was about 6.47 mm, and specifically the increase in width was about 5.11 mm. The results obtained are in no way inferior to those obtained during the implementation of the protocol of directed bone regeneration. In this case, the SMART method was used to form adequate horizontal ridge parameters in order to maintain the required soft tissue profile. Separation of the flap would lead to loss of the integrity of the gingival profile and the need to remove the root of the 8th tooth. Augmentation was performed using a tunnel subperiosteal technique using an inorganic bone substitute and plasma derivative enriched with platelet growth factors. The selection of the biomaterial was carried out taking into account the low dynamics of its replacement and the ability to maintain the necessary contour of tissues in the area of intervention (photos 13-15).

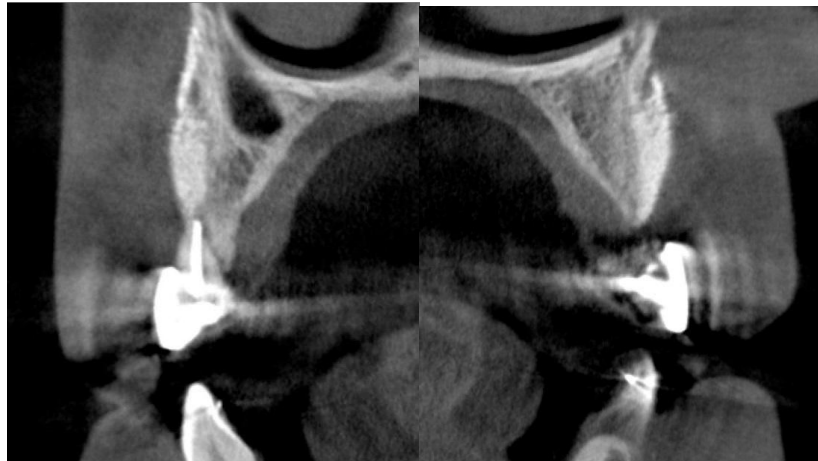

Photo 13. Horizontal augmentation without separation of the flap in the area of the 6th tooth using the SMART method.

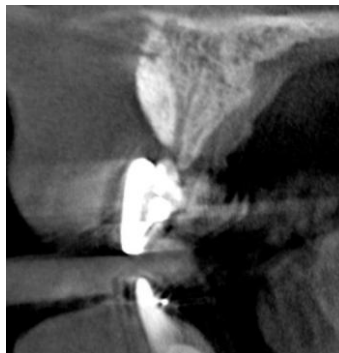

Photo 14. Horizontal augmentation without flap separation in the area of the 7th tooth using the SMART method.

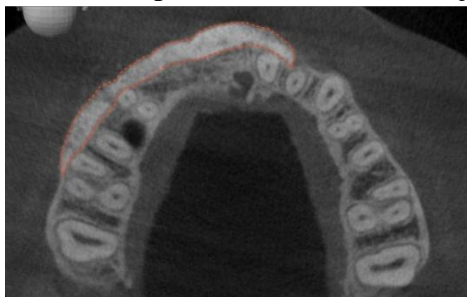Recombinant platelet-derived growth factor BB has been used to stimulate bone formation and improve soft tissue healing. The SMART method does not involve the use of locking screws or other devices to support the required amount of space. The degree of horizontal enlargement is

the result of a clear formation of the boundaries of the tunnel and the subperiosteal pocket, within which platelet aggregation is carried out, taking into account the dispersion of the bone substitute.

Unlike traditional methods of targeted bone regeneration, the described membranes are not mandatory when implementing the SMART approach. Earlier, the author conducted an experimental study, during which it was established that the use of membranes is not critically necessary to ensure the integration and mineralization of the graft. In addition, Simion and colleagues reported that bone regeneration with the additional use of growth factor is more successful in conditions of subperiosteal access, even without the use of barrier membranes. Considering that in this case neither decortication nor penetration of the bone marrow space was performed, the periosteum could play the role of a potential source of progenitor cells, which ensure the formation of bone tissue.

Since recession was already present in the area of the 5th tooth, the scope of SMART intervention was expanded to horizontal augmentation and neighboring areas, in which there were also signs of digescence and thinning of the buccal cortical plates (photo 16).

Photo 16. The augmentation area was expanded to the area of adjacent teeth.



The areas of intervention after augmentation are shown in photo 16 (they can be compared with photo 4 taken before the start of treatment). This approach, however, is technically- and manipulationally- sensitive. Unlike the lateral subperiosteal methods, the SMART method is based on the formation of a laparoscopic tunnel from the area of the removed incision to the area in need of augmentation. After that, a subperiosteal pocket is recreated for preserving biomaterial particles (photos 17 and 18).

Photo 17. Illustration of the SMART method: incision formation and subperiosteal access.

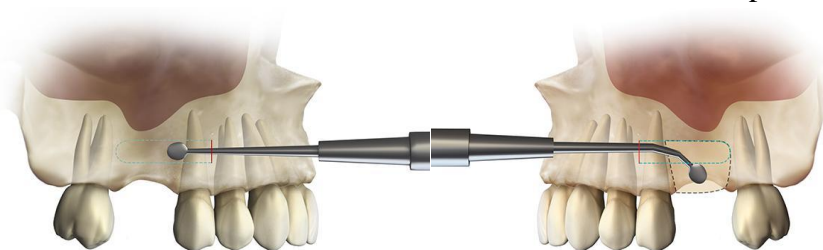
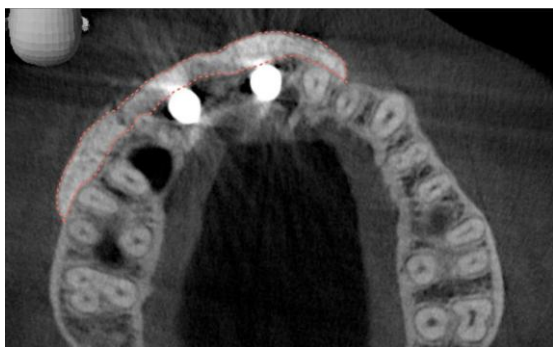
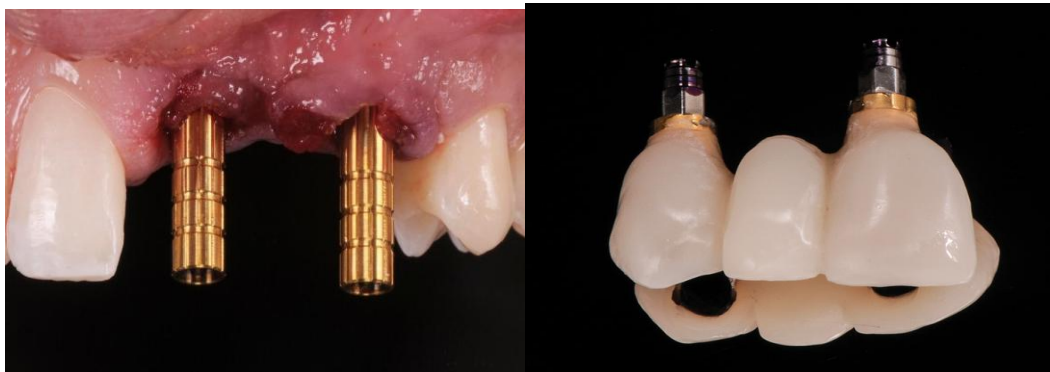


Photo 18. Illustration of the SMART method: formation of a subperiosteal pocket for graft packaging.

Thus, the absence of injury in the periosteal area and the accompanying inflammatory reaction only contributes to the healing of the surgical area. A whole set of surgical instruments has been

developed to perform all the procedures of the SMART protocol. The stabilization and integration of the bone substitute takes place over the course of 6 months. After that, teeth 6 and 8 were removed, and implants were immediately installed in their place without flap separation (photos 19-21).

Photos 19-21. Fixing of three single provisional restorations.



The gum tissues showed a moderate degree of inflammation as a result of the difficulty of access for adequate hygiene, which was provoked by the presence of a post-orthodontic splint for as long as 9 months. Conical structures were selected as implants for installation, which demonstrated excellent primary stability after installation (photos 22 and 23).

Photos 22-23. The implants installed in the area of 6 and 8 teeth had a conical design.

The TOC of both implants exceeded 45 Nm during installation, which allowed them to be directly loaded. During the same reception, a screw-type storage structure consisting of three units was installed (photo 20). In addition, small occlusal pads were performed in the area of the premolars and molars to separate the bite, and thus ensure the prevention of centric excursion movements in the area of the implants during their osseointegration.

After 3 months, these composite linings were removed, and the area of the cutting edges of the provisional restorations was modified in order to ensure contact with antagonistic teeth. The patient did not report any complaints, discomfort, or symptoms during the period of osseointegration of the intraosseous supports. The implants remained stable, and all critical clinical parameters were within the normal range. The X-ray evaluation confirmed the presence of adequate contact between the bone and the implant surface, as well as the optimal level of the bone ridge in the periimplant area. The external soft tissues also showed no abnormalities (photos 24-27).

Photo 24. X-ray 3 months after treatment.

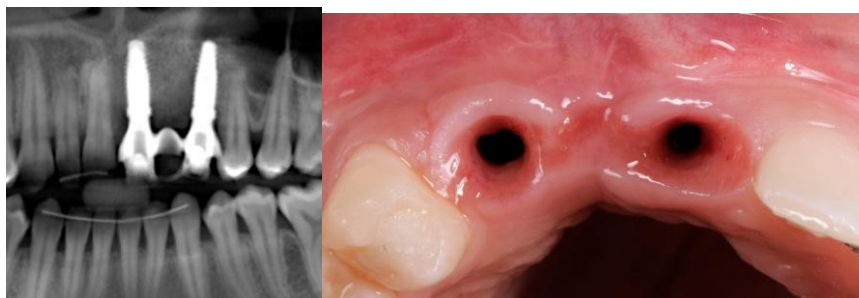
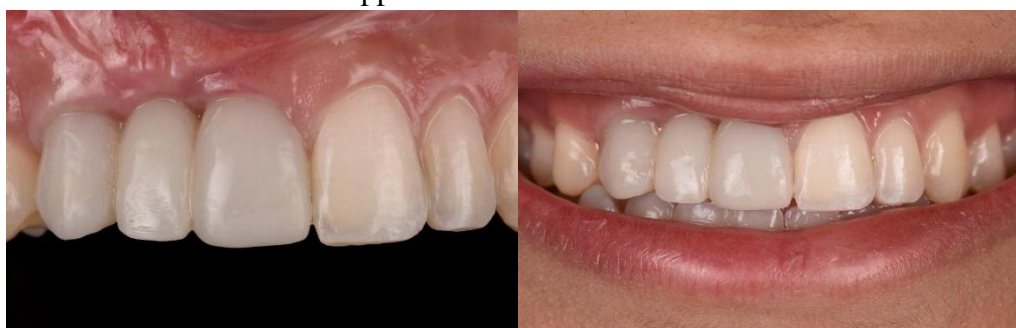

Photo 25. The appearance of soft tissues after 3 months.

Photo 25. The appearance of soft tissues after 3 months.



After that, the patient returned to study at a medical college, and, taking into account this fact, as well as the change in geographical location, she used milled polymethylmethacrylate dental restorations for the next 18 months. It is planned to replace these structures with final ones in the near future.

Discussion

It is always necessary to evaluate the prognosis of treatment, especially in clinical cases where the risk of potential complications is quite high, and the outcome of treatment significantly affects the formation of the aesthetic profile of a smile. Based on this, it should be remembered that bone augmentation also significantly affects the architecture of the surrounding soft tissues. In this clinical case, a three-dimensional reconstruction of a complex iatrogenic defect was performed using the technique of orthodontic tooth extrusion, which helped achieve the necessary vertical ridge parameters, and minimally invasive augmentation techniques for reconstructing the horizontal component of the bone. This interdisciplinary approach has made it possible to ensure predictable treatment results while maintaining adequate soft tissue parameters. The volume of the gum, the level of its marginal edge and the aesthetic architecture were successfully restored, while avoiding many step-by-step transplantation procedures. The only drawback was the length of the papillae adjacent to the area of the defect, which did not correspond to that on the opposite side. The method used ensured the reconstruction of sufficient bone volume while minimizing all possible potential risks characteristic of targeted bone regeneration. However, this procedure remains technically complex and manipulational

sensitive, and its implementation requires not only special tools, but also an understanding of surgical methodology, specific training and experience.

Conclusions

Orthodontically directed tooth extrusion, together with a minimally invasive approach to augmentation, helps to achieve effective results in the treatment of gingival-alveolar defects in the aesthetic area, while ensuring complete aesthetic and functional rehabilitation of the patient. To determine the full potential of this approach and its limitations, it is necessary to ensure that more targeted research is conducted.

References

1. Asrorovna, X. N., Baxriddinovich, T. A., Bustanovna, I. N., Valijon O'g'li, D. S., & Qizi, T. K. F. (2021). Clinical Application Of Dental Photography By A Dentist. *The American Journal of Medical Sciences and Pharmaceutical Research*, 3(09), 10-13.
2. Ugli, A. A. A., & Bustanovna, I. N. (2024). STUDY OF THE CONDITION OF PARODONT IN PERIODONTITIS IN FETAL WOMEN. *European International Journal of Multidisciplinary Research and Management Studies*, 4(05), 149-156.
3. Kizi, J. O. A., & Bustanovna, I. N. (2024). FAMILIARIZATION WITH THE HYGIENIC ASSESSMENT OF THE CONDITION OF THE ORAL MUCOSA IN ORTHOPEDIC TREATMENT. *European International Journal of Multidisciplinary Research and Management Studies*, 4(05), 89-96.
4. Bustanovna, I. N. (2024). Determination of the Effectiveness of Dental Measures for the Prevention of Periodontal Dental Diseases in Workers of the Production of Metal Structures. *International Journal of Scientific Trends*, 3(5), 108-114.
5. Bustanovna, I. N. (2022). Assessment of clinical and morphological changes in the oral organs and tissues in post-menopause women. *Thematics Journal of Education*, 7(3).
6. Bustanovna, I. N., & Verdikulovich, N. A. (2022). ПРОФИЛАКТИКА И ЛЕЧЕНИЯ КАРИЕСА У ПОСТОЯННЫХ ЗУБОВ. *JOURNAL OF BIOMEDICINE AND PRACTICE*, 7(1).
7. Bustanovna, I. N. (2024). PATHOGENESIS OF PERIODONTAL DISEASE IN ELDERLY WOMEN. *Лучшие интеллектуальные исследования*, 21(3), 25-29.
8. Bustanovna, I. N. (2024). TO STUDY THE HYGIENIC ASSESSMENT OF THE CONDITION OF THE ORAL MUCOSA DURING ORTHOPEDIC TREATMENT. *Лучшие интеллектуальные исследования*, 21(1), 9-15.
9. Bustanovna, I. N. (2024). CLINICAL AND LABORATORY CHANGES IN PERIODONTITIS. *Journal of new century innovations*, 51(2), 58-65.
10. Bustanovna, I. N. (2024). Morphological Changes in Oral Organs and Tissues in Women after Menopause and their Analysis. *International Journal of Scientific Trends*, 3(3), 87-93.
11. Bustanovna, I. N. (2024). Hygienic Assessment of The Condition of The Oral Mucosa After Orthopedic Treatment. *International Journal of Scientific Trends*, 3(3), 56-61.

12. Bustanovna, P. I. N. (2024). Further Research the Features of the Use of Metal-Ceramic Structures in Anomalies of Development and Position of Teeth. *International Journal of Scientific Trends*, 3(3), 67-71.
13. Bustanovna, I. N. (2024). The Effectiveness of the Use of the Drug " Proroot MTA" in the Therapeutic and Surgical Treatment of Periodontitis. *International Journal of Scientific Trends*, 3(3), 72-75.
14. Bustanovna, P. I. N. (2024). Research of the Structure of Somatic Pathology in Patients with Aphthous Stomatitis. *International Journal of Scientific Trends*, 3(3), 51-55.
15. Bustanovna, I. N., & Abdusattor o'g, A. A. A. (2024). Analysis of Errors and Complications in the Use of Endocal Structures Used in Dentistry. *International Journal of Scientific Trends*, 3(3), 82-86.
16. Bustanovna, I. N. (2024). Complications Arising in the Oral Cavity after Polychemotherapy in Patients with Hemablastoses. *International Journal of Scientific Trends*, 3(3), 62-66.
17. Bustanovna, I. N., & Sharipovna, N. N. (2023). Research cases in women after menopause clinical and morphological changes in oral organs and their analysis. *Journal of biomedicine and practice*, 8(3).
18. Bustonovna, I. N., & Sharipovna, N. N. (2023). Essential Factors Of Etiopathogenesis In The Development Of Parodontal Diseases In Post-Menopasis Women. *Eurasian Medical Research Periodical*, 20, 64-69.
19. Fakhridin, C. H. A. K. K. A. N. O. V., Shokhruh, S. A. M. A. D. O. V., & Nilufar, I. S. L. A. M. O. V. A. (2022). ENDOKANAL PIN-KONSTRUKSIYALARNI ISHLATISHDA ASORATLAR VA XATOLAR TAHLILI. *JOURNAL OF BIOMEDICINE AND PRACTICE*, 7(1).
20. Очиллов, Х. У., & Исламова, Н. Б. (2024). Особенности артикуляции и окклюзии зубных рядов у пациентов с генерализованной формой повышенного стирания. *SAMARALI TA'LIM VA BARQAROR INNOVATSIYALAR JURNALI*, 2(4), 422-430.
21. Ortikova, N., & Rizaev, J. (2021, May). The Prevalence And Reasons Of Stomatophobia In Children. In *E-Conference Globe* (pp. 339-341).
22. Ortikova, N. (2023). ANALYSIS OF ANESTHESIA METHODS FOR DENTAL FEAR AND ANXIETY. *Центральноазиатский журнал академических исследований*, 1(1), 8-12.
23. Ortikova, N. K. (2023). DENTAL ANXIETY AS A SPECIAL PLACE IN SCIENTIFIC KNOWLEDGE. *SCHOLAR*, 1(29), 104-112.
24. Исламова, Н. Б. (2024). ПАРОДОНТ КАСАЛЛИКЛАРИДА ОРГАНИЗМДАГИ УМУМИЙ ЎЗГАРИШЛАРНИ ТАҲЛИЛИ ВА ДАВОЛАШ САМАРАДОРЛИГИНИ ТАКОМИЛЛАШТИРИШ. *ОБРАЗОВАНИЕ НАУКА И ИННОВАЦИОННЫЕ ИДЕИ В МИРЕ*, 43(7), 18-22.
25. Islamova, N. B., & Chakkonov, F. K. (2021). Changes in the tissues and organs of the mouth in endocrine diseases. *Current Issues in Dentistry*, 320-326.

26. Исламова, Н. Б., & Исломов, Л. Б. (2021). Особенности развития и течения заболеваний полости рта при эндокринной патологии. ББК, 56, 76.
27. Исламова, Н. Б., & Назарова, Н. Ш. (2023). СУРУНКАЛИ ТАРҚАЛГАН ПАРОДОНТИТ БИЛАН КАСАЛЛАНГАН ПОСТМЕНОПАУЗА ДАВРИДАГИ АЁЛЛАРНИНГ ПАРОДОНТ ТЎҚИМАСИНИНГ ДАВОЛАШ САМАРАДОРЛИГИ ОШИРИШ. ЖУРНАЛ СТОМАТОЛОГИИ И КРАНИОФАЦИАЛЬНЫХ ИССЛЕДОВАНИЙ, 4(2).
28. Исламова, Н. Б. (2024). ПАРОДОНТИТ КАСАЛЛИГИДА
29. Nazarova, N. S., & Islomova, N. B. (2022). postmenopauza davridagi ayollarda stomatologik kasalliklarining klinik va mikrobiologik ko'rsatmalari va mexanizmlari. Журнал "Медицина и инновации", (2), 204-211.
30. Nazarova, N. S., & Islomova, N. B. (2022). postmenopauza davridagi ayollarda stomatologik kasalliklarining klinik va mikrobiologik ko'rsatmalari va mexanizmlari. Журнал "Медицина и инновации", (2), 204-211.
31. Sulaymonova, Z. Z., & Islamova, N. B. (2023, May). TAKING IMPRESSIONS IN THE ORAL CAVITY AND THEIR REDUCTION. In Conferences (pp. 21-23).
32. Sharipovna, N. N., & Bustonovna, I. N. (2022). Etiopatogenetic factors in the development of parodontal diseases in post-menopasis women. The american journal of medical sciences and pharmaceutical research, 4(09).
33. Sarimsokovich, G. M. (2023). LATEST METHODS OF STUDY OF PERIODONTAL DISEASE IN WOMEN. European International Journal of Multidisciplinary Research and Management Studies, 3(10), 242-250.
34. DENTAL PROSTHETICS. Лучшие интеллектуальные исследования, 18(4), 31-35.
35. Содикова, Ш. А., & Исламова, Н. Б. (2021). Оптимизация лечебно-профилактических мероприятий при заболеваниях пародонта беременных женщин с железодефицитной анемией. In Актуальные вопросы стоматологии (pp. 434-440).
36. Чакконов, Ф. Х. (2021). ЯТРОГЕННЫЕ ОШИБКИ В СТОМАТОЛОГИИ И ИХ ПРИЧИНЫ. In Актуальные вопросы стоматологии (pp. 925-930).
37. ЧАККОНОВ, Ф., САМАДОВ, Ш., & ИСЛАМОВА, Н. (2022). ENDOKANAL PIN-KONSTRUKSIYALARNI ISHLATISHDA ASORATLAR VA XATOLAR TANHLILI. ЖУРНАЛ БИОМЕДИЦИНЫ И ПРАКТИКИ, 7(1).
38. Xusanovich, C. F., Orzimurod, T., Maruf, U., & Ollomurod, X. (2023). PROSTHETICS A COMPLETE REMOVABLE PROsthESIS BASED ON IMPLANTS. European International Journal of Multidisciplinary Research and Management Studies, 3(11), 122-126.
39. Xusanovich, C. F., Sunnat, R., & Sherali, X. (2024). CLASP PROSTHESES-TECHNOLOGY IMPROVEMENT. European International Journal of Multidisciplinary Research and Management Studies, 4(03), 152-156.